

Research Article

# Prophylactic and Ameliorative Effect of *N*-Acetylcysteine on Doxorubicin-Induced Neurotoxicity in Wister Rats

Walaa I. Mohammed<sup>1</sup>, Rania A. Radwan<sup>2</sup>, and Hoda M. Elsayed<sup>3</sup>

<sup>1</sup>Department of Clinical Pharmacology, Faculty of Medicine, Sohag University, Egypt

<sup>2</sup>Department of Forensic medicine and clinical toxicology, Faculty of Medicine, Sohag University, Egypt

<sup>3</sup>Department of Histology, Faculty of Medicine, Sohag University, Egypt

**Abstract.** Doxorubicin (DOX) is an anthracycline antibiotic and a quinone-containing chemotherapeutic drug used for various types of cancers. However, as with most anticancer drugs, it causes many toxic effects, one of them is cognitive impairment. The present study investigated the prophylactic and ameliorative effect of n-acetylcysteine (NAC) against DOX-induced neurotoxicity in rats. Rats were divided into four groups. Control group: rats received saline. NAC treated group: rats received NAC (100 mg/kg, p.o.) daily for 35 days. DOX-treated group: rats received DOX (4 mg/kg, i.p.) for four weeks on day 7, 14, 21 and 28. DOX+NAC treated group 1: rats received NAC (100 mg/kg, p.o.) daily for 35 days and DOX (4 mg/kg, i.p.) for four weeks on day 7, 14, 21 and 28). DOX+NAC treated group 2: rats received NAC (100 mg/kg, p.o.) daily started at the 7th day of the experiment till the end of the experiment and DOX (4 mg/kg, i.p.) for four weeks on day 7, 14, 21 and 28. The present results showed a significant reduction in the body weight, which was associated with a significant increase in brain to body weight ratio in DOX-treated rats. Tumor necrosis factor (TNF- $\alpha$ ) level, malondialdehyde (MDA) and total protein levels were significantly elevated. Whilst, reduced glutathione (GSH) and glutathione peroxidase (GPx) levels were significantly decreased. Moreover, there were histopathological abnormalities in the brain tissue of DOX-treated rats, as most of the neurons degenerated and the blood vessels surrounded with wide perivascular spaces. In addition, the neuropil was vacuolated. The present study demonstrated that NAC has a neuroprotective effect on the brain damage induced by DOX, through inhibition of inflammation and oxidative stress. This neuroprotective effect was more pronounced in DOX+NAC treated group 1, as it produced a significant increase in brain GSH and GPx levels and more improvement in the histopathological abnormality compared to DOX+NAC treated group 2.

**Keywords:** Doxorubicin, N-Acetylcysteine, neurotoxicity, tumor necrosis factor, antioxidant.

**Corresponding Author**

Walaa I. Mohammed  
walaa\_mohamed@med  
.sohag.edu.eg

**Editor**

Helen Kwanashie

**Dates**

Received 9 October 2018

Accepted 3 January 2019

Copyright © 2019 Walaa I. Mohammed et al. This is an open access article distributed under the Creative Commons Attribution License, which permits unrestricted use, distribution, and reproduction in any medium, provided the original work is properly cited.

## 1. Introduction

Doxorubicin (DOX) is an anthracycline antibiotic and a quinone-containing chemotherapeutic drug, usually used for chemotherapy of breast cancer and other cancers [1]. The mechanism of DOX is chelating DNA, inhibiting topoisomerase II and producing large amounts of free radicals to kill cancer cells [2]. However, this mechanism of action is implicated in the toxicity of several non-targeted organs particularly the heart, kidney, and brain [3] and limits its dosage in cancer patients.



In addition, cognitive impairments were reported to have adverse effects on patients' daily activities [4]. Doxorubicin does not pass through the blood-brain barrier (BBB), so the decline in cognition occurs with its administration is attributed to the peripheral increase in the circulating tumor necrosis factor (TNF- $\alpha$ ) [5–7]. TNF- $\alpha$  migrates across the BBB and activates glial cells to release large amounts of the local TNF- $\alpha$  in the cortex and hippocampus leading to inflammation and induced oxidative stress in the brain [8]. Thus, the increase in TNF- $\alpha$  level may be a reason for doxorubicin-induced oxidative stress and its central nervous system injury [9]. Antagonizing circulating TNF- $\alpha$  with TNF- $\alpha$  antibody led to a manifest decrease in TNF- $\alpha$  levels and the observed mitochondrial dysfunction in brain tissues [5].

NADPH-cytochrome P-450 converts DOX to its semiquinone radical, which then reoxidized and regenerated by oxygen producing superoxide anions. Increased level of superoxide anions elevates the circulating TNF- $\alpha$  level that can directly cross the BBB [10].

N-Acetylcysteine (NAC) is an acetylated precursor of the amino acid L-cysteine [11]. It used as an antidote for paracetamol intoxication and as a mucolytic agent [12]. NAC is an important cellular antioxidant that decreases inflammation in various diseases. It is also a glutathione precursor and inhibits lipid peroxidation and proinflammatory cytokines [13].

In addition, NAC has a wide spectrum of actions and different applications in multiple systems. It can pass through the BBB and cure brain dysfunctions and neuropathies. Also, it applied for the treatment of vascular and nonvascular neurological disorders and modulates glutamatergic, neurotrophic and inflammatory pathways [14].

This study aimed to evaluate the potential protective and ameliorative effect of NAC against doxorubicin-induced neurotoxicity in rats, through some of its anti-inflammatory and antioxidant effects.

## 2. Materials and Methods

### 2.1. Materials

N-Acetylcysteine was purchased from AK Scientific, Inc. (USA), while Doxorubicin was purchased as Adriblastina vials from Pharmacia Italia S.P.A., Italy.

Kits for determination of TNF- $\alpha$  was obtained from Wuhan EIAab Science Co. Ltd (China). Malondialdehyde (MDA), reduced glutathione (GSH) and glutathione peroxidase (GPx) kits were obtained from Bio-diagnostic Company, Egypt. While kits for determination of total protein was obtained from Sigma-Aldrich (USA).

### 2.2. Animals

The study was conducted on 50 adult male Wister albino rats, weighing 150-200g (initial weight). Rats were purchased from the animal house, Faculty of Medicine, Assiut University, Egypt, and were housed in the animal facility, Faculty of Medicine, Sohag University and maintained in a controlled environment under standard conditions of temperature ( $25 \pm 2^\circ\text{C}$ ). A time controlled system provided 12 hours of light and 12 hours of dark was applied. All rats were fed freely on rodent chow diet. The experimental protocol was carried out and approved

according to the guidelines of the Medical Research Ethics Committee of Faculty of Medicine, Sohag University, Egypt. (Approval No. 29/2018).

### **2.3. Equipment used**

Tissue homogenizer: Wise-Tis, HG-15D, Germany.

Spectrophotometer: analytik jena, Germany.

ELISA microplate reader: AWARENESS Stat Fax- 2200, USA.

### **2.4. Experimental design**

Rats were left for one week-acclimatization period and then divided into five groups, ten animals each. The duration of the experiment was 35 days and designed as follow:

#### **2.4.1. Control group**

Rats were received normal saline orally (p.o.) by gastric tube daily for 35 days.

#### **2.4.2. NAC treated group**

Rats were received NAC in normal saline at the dose of 100 mg/kg (p.o.) [15] daily for 35 days.

#### **2.4.3. DOX treated group**

Rats were received DOX (intraperitoneally, i.p.) at the dose of 4 mg/kg [16] in normal saline once a week for four weeks on day 7, 14, 21 and 28.

#### **2.4.4. Two DOX + NAC treated groups**

##### **DOX + NAC treated group 1 (DOX + NAC1)**

Rats received NAC (100 mg/kg p.o.) daily for 35 days and 4 mg/kg of DOX (i.p.) in normal saline once a week for four weeks on day 7, 14, 21 and 28.

##### **DOX + NAC treated group 2 (DOX + NAC2)**

Rats received NAC (100 mg/kg p.o.) daily started at the 7th day of the experiment till the end of the experiment and 4 mg/kg of DOX (i.p.) in normal saline once a week for four weeks on day 7, 14, 21 and 28.

Body weight of each rat was measured daily during the experimental period. The dose of the test drugs to be given was calculated daily based on the body weight of the experimental animals to ensure administration of the fixed dose.

At the end of the experiment, rats were weighted before euthanized by decapitation. Immediately, the brain was removed, washed with ice-cold phosphate buffer solution (pH 7.4), dried on filter paper and weighed. The brain tissue from each rat was divided for assessment of brain toxicity on biochemical and histopathological levels.

## **2.5. Biochemical assays in the brain tissue**

### **2.5.1. Preparation of tissue homogenates**

Brain samples were homogenized in 10ml ice-cold potassium phosphate buffer (50 mM, pH 7.4) per gram tissue (v/w) for the assay of brain TNF- $\alpha$ , GSH, GPx, MDA as well as total protein levels. All homogenates were centrifuged at 4000 rpm for 15 min at 4°C. The supernatant was separated and kept at -20°C until the time of analysis.

### **2.5.2. Determination of TNF- $\alpha$ level**

Tumor necrosis factor - $\alpha$  in the brain homogenate was measured using enzyme-linked immunosorbent assay (ELISA) specific for a rat. The TNF- $\alpha$  level was expressed as pg/g tissue.

### **2.5.3. Determination of reduced glutathione level**

Reduced glutathione was measured in the brain tissue homogenate by a colorimetric method as described by Beutler et al. [17]. The method was based on the reduction of 5,5' dithiobis (2-nitrobenzoic acid) with glutathione producing a yellow compound. The reduced chromogen directly proportional to GSH concentration and its absorbance was measured at 405 nm. GSH level was expressed in mg/g tissue.

### **2.5.4. Determination of glutathione peroxidase level**

Glutathione peroxidase was determined in the brain tissue homogenate by a colorimetric method as described by Paglia and Valentine [18]. GPx level was expressed in U/g tissue.

### **2.5.5. Determination of lipid peroxidation level**

Malondialdehyde level is an indicator of lipid peroxidation. MDA in the brain tissue homogenate was detected by a colorimetric method as described by Ohkawa et al. [19]. This method depends on the spectrophotometric measurement of the color produced during the reaction of a thiobarbituric acid with MDA. They react in an acidic medium for 30 min to form a thiobarbituric acid reactive product. The absorbance of the resultant pink product was measured at 534 nm. MDA level was expressed in nmol/g tissue.

### 2.5.6. Determination of total protein level

Protein was determined by the method of Bradford [20] by using bovine serum albumin as a standard.

## 2.6. Histopathological studies

Samples of the brain tissue were excised, fixed in 10% formal saline, dehydrated in ascending grades of ethanol, cleared in xylene and embedded in paraffin wax [21]. Sections (5  $\mu$ m thick) were cut and stained with hematoxylin and eosin (H&E).

## 2.7. Statistical analysis of data

Data were expressed as mean  $\pm$  standard error (SE). Statistical difference between studied groups was analyzed using one-way analysis of variance (ANOVA). In cases where ANOVA showed significant differences, Tukey post hoc test was performed to compare the changes among individual groups. The difference was regarded as significant when  $P < 0.05$ . All statistical analyses were performed using SPSS statistical version 20 software package.

## 3. Results

### 3.1. General observation and mortality

The general appearance of all groups was inspected during the study. In all DOX-treated groups, a red colored lesion was observed at the site of injection. Signs of general toxicity such as weakness, enlargement of the abdomen, red colored discharge around the nose and mouth were observed, and they were more extensive in the DOX-treated group than in DOX+NAC treated groups. Moreover, rats in the DOX-treated group showed decline in their feed and water consumption during the drug treatment period as compared to the control group. On the other hands, in the DOX+NAC treated groups, feed and water consumption increased as compared to the DOX-treated group.

The mortality rate in the DOX-treated group was high and reached 30%, while in DOX+NAC2 the mortality rate was low and reached 10%. No mortality was recorded in both NAC treated and DOX+NAC1 groups.

### 3.2. Changes in body weight and brain weight to body weight ratio

There was an insignificant change ( $P > 0.05$ ) in the final body weight in the NAC treated group compared to the control group. On the other hand, the final body weight in DOX-treated group decreased significantly ( $P < 0.05$ ) when compared to the control group. In DOX+NAC treated groups, the final body weight was increased but not statistically significant ( $P > 0.05$ ) compared to the DOX-treated group (Table 1).

**Table 1:** Effect of oral administration of n-acetylcysteine on body weight in doxorubicin- induced neurotoxicity in rats.

Groups	N	Initial body weight(g)	Final body weight (g)	Weight gain(g)
Control	10	172.75 ± 5.34	261.58 ± 4.48	86.51 ± 4.92
NAC treated	10	171.75 ± 5.06	262.70 ± 4.07	89.94 ± 5.92
DOX-treated	7	172.3 ± 4.23	143.36 ± 5.65*	-26.93 ± 1.75*
DOX+NAC1	10	171.05 ± 5.33	159.50 ± 6.65	-10.56 ± 1.14 <sup>a</sup>
DOX+NAC2	9	172.5 ± 5.07	156.78 ± 5.34	-14.33 ± 1.06 <sup>a</sup>

Each value represents the mean ± SE. Data were analyzed by one-way ANOVA followed by Tukey post hoc test.

N = the number of animals in each group, NAC = n-acetylcysteine, DOX = doxorubicin, DOX+NAC1 = DOX+NAC treated group 1, DOX+NAC2 = DOX+NAC treated group 2.

\*Significant difference at  $P < 0.05$  Vs. Control group.

<sup>a</sup>Significant difference at  $P < 0.05$  Vs. DOX-treated group.

**Table 2:** Effect of oral administration of n-acetylcysteine on brain weight and brain weight/ body weight ratio in doxorubicin- induced neurotoxicity in rats.

Groups	N	Brain weight (g)	Brain weight/ Body weight Ratio
Control	10	1.26 ± 0.07	0.48 ± 0.03
NAC treated	10	1.15 ± 0.09	0.44 ± 0.03
DOX-treated	7	1.64 ± 0.8*	1.15 ± 0.06*
DOX+NAC1	10	1.42 ± 0.06 <sup>a</sup>	0.09 ± 0.04 <sup>a</sup>
DOX+NAC2	9	1.46 ± 0.05	0.92 ± 0.04 <sup>a</sup>

Each value represents the mean ± SE. Data were analyzed by one-way ANOVA followed by Tukey post hoc test.

N = the number of animals in each group, NAC = n-acetylcysteine, DOX = doxorubicin, DOX+NAC1 = DOX+NAC treated group 1, DOX+NAC2 = DOX+NAC treated group 2.

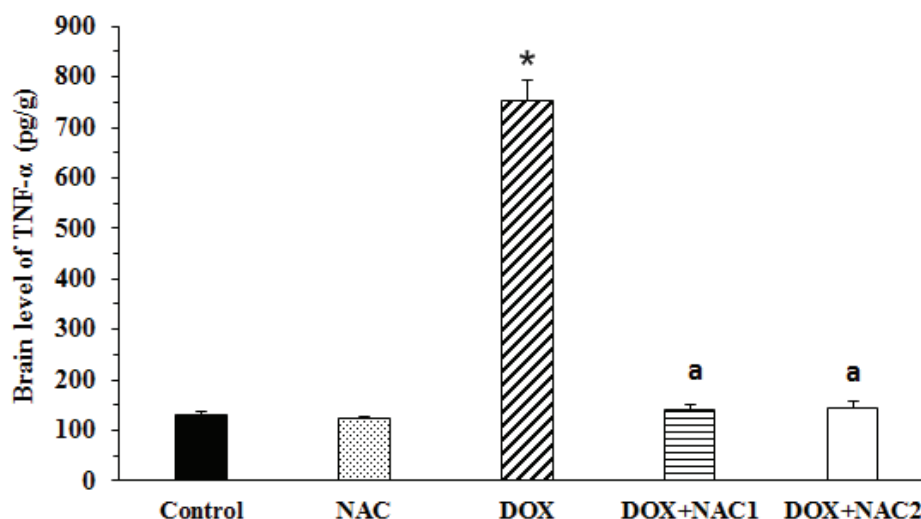
\*Significant difference at  $P < 0.05$  Vs. Control group.

<sup>a</sup>Significant difference at  $P < 0.05$  Vs. DOX-treated group.

The NAC treated group showed an insignificant change ( $P > 0.05$ ) in brain weight to body weight ratio compared to the control group. The brain weight to body weight ratio in the DOX-treated group was significantly increased ( $P < 0.05$ ) compared to the control group. The brain weight to body weight ratio in both DOX+NAC1 and DOX+NAC2 groups was significantly ( $P < 0.05$ ) decreased compared to DOX group with an insignificant difference ( $P > 0.05$ ) between them (Table 2).

### 3.3. Changes in brain TNF- $\alpha$ level

The levels of TNF- $\alpha$  in the brain tissue of the NAC treated group showed an insignificant change ( $P > 0.05$ ) compared to the control group. On the other hand, the levels of TNF- $\alpha$  in the brain tissue was significantly increased ( $P < 0.05$ ) in the DOX-treated group compared to the control group. Treatments of the rats with NAC plus DOX (i.e. DOX+NAC treated groups 1 and 2) produced a significant decrease in the brain TNF- $\alpha$  level compared to the DOX-treated group



**Figure 1: Effect of oral administration of n-acetylcysteine on the brain level of TNF- $\alpha$  in doxorubicin-induced neurotoxicity in rats.** Each value represents the mean  $\pm$  SE. Data were analyzed by one-way ANOVA followed by Tukey post hoc test. NAC = n-acetylcysteine, DOX = doxorubicin, DOX+NAC1 = DOX+NAC treated group 1, DOX+NAC2 = DOX+NAC treated group 2. \*Significant difference at  $P < 0.05$  Vs. Control group. <sup>a</sup>Significant difference at  $P < 0.05$  Vs. DOX-treated group.

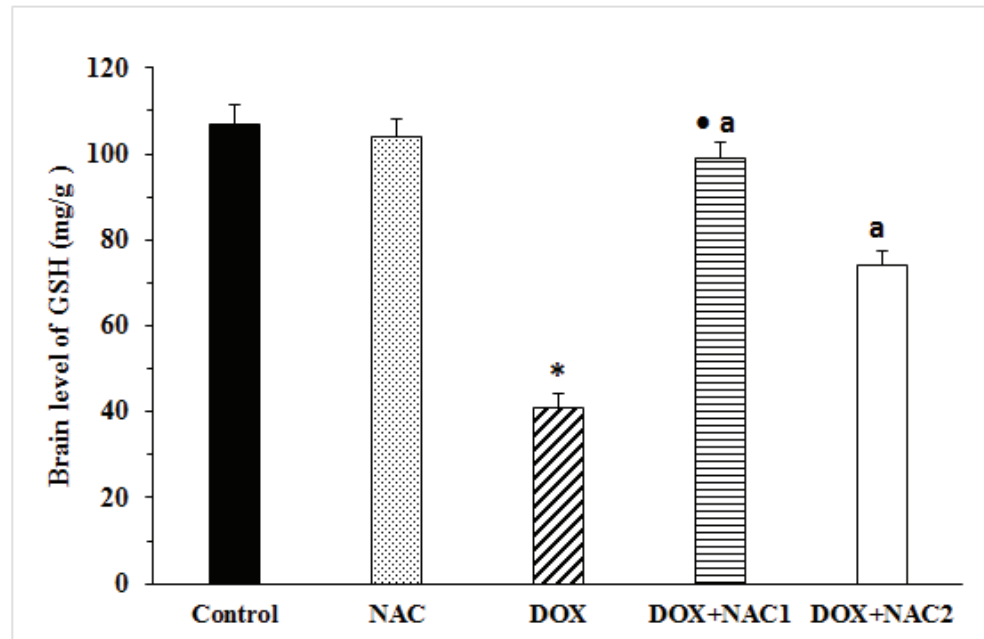
( $P < 0.05$ ), while no significant difference between the two groups ( $P > 0.05$ ) was statistically detected (Figure 1).

### 3.4. Changes in brain GSH level

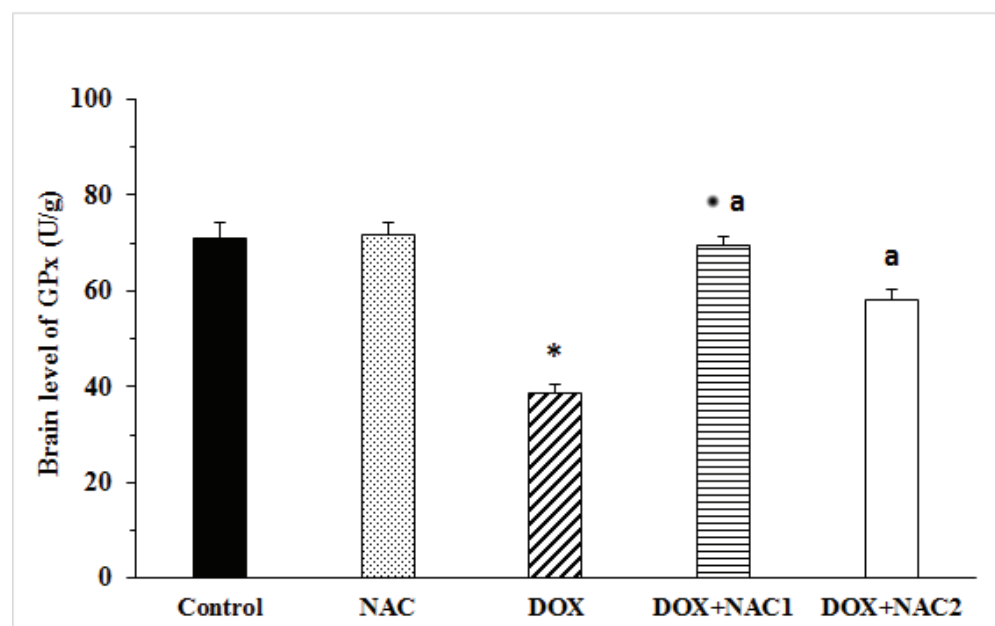
NAC treated group showed an insignificant change ( $P > 0.05$ ) in GSH level in the brain tissue compared to the control group. However, a significant decrease ( $P < 0.05$ ) in the brain GSH level was recorded in the DOX-treated group compared to the control group. Animals treated with NAC plus DOX (DOX+NAC treated groups 1 and 2) showed a significant increase ( $P < 0.05$ ) in the brain level of GSH compared to the DOX-treated group. Moreover, DOX+NAC1 produced a significant increase ( $P < 0.05$ ) in the brain GSH compared to DOX+NAC2 (Figure 2).

### 3.5. Changes in brain GPx level

Glutathione peroxidase level in the brain tissue of the NAC treated group showed an insignificant change ( $P > 0.05$ ) compared to the control group. Moreover, the brain level of GPx was significantly decreased ( $P < 0.05$ ) in the DOX-treated group compared to the control group (Figure 3). NAC supplementation in both DOX+NAC treated groups 1 and 2 produced a significant elevation ( $P < 0.05$ ) in the brain GPx level compared to the DOX-treated group. The results revealed that the DOX+NAC1 was more effective ( $P < 0.05$ ) than DOX+NAC2 in the elevation of brain GPx level to reach near to the control level (Figure 3).

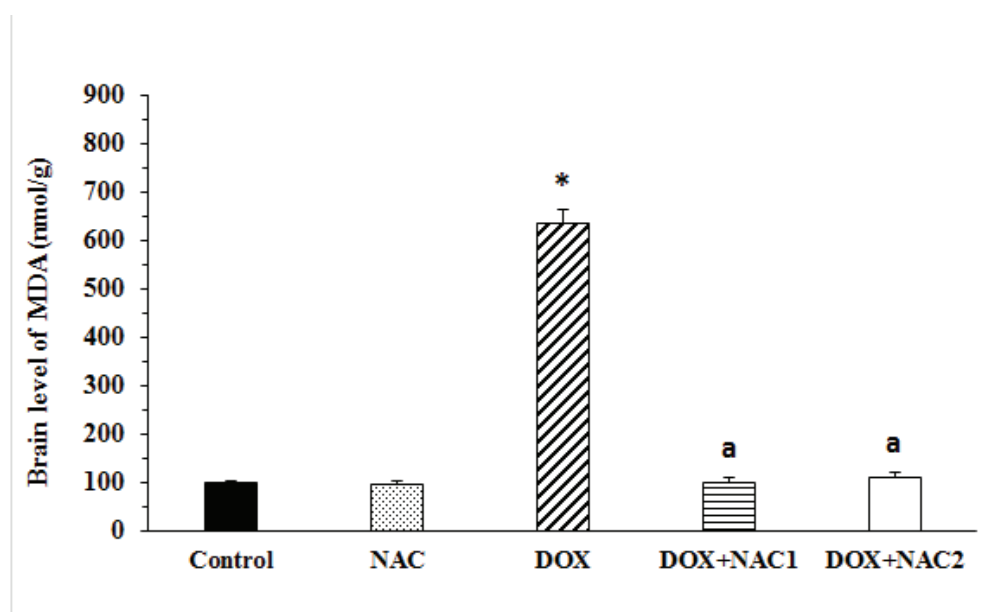


**Figure 2: Effect of oral administration of n-acetylcysteine on the brain level of GSH in doxorubicin-induced neurotoxicity in rats.** Each value represents the mean  $\pm$  SE. Data were analyzed by one-way ANOVA followed by Tukey post hoc test. NAC = n-acetylcysteine, DOX = doxorubicin, DOX+NAC1 = DOX+NAC treated group 1, DOX+NAC2 = DOX+NAC treated group 2. \*Significant difference at  $P < 0.05$  Vs. Control group. <sup>a</sup>Significant difference at  $P < 0.05$  Vs. DOX-treated group. •Significant difference at  $P < 0.05$  Vs. DOX+NAC2 treated group.



**Figure 3: Effect of oral administration of n-acetylcysteine on the brain level of GPx in doxorubicin-induced neurotoxicity in rats.** Each value represents the mean  $\pm$  SE. Data were analyzed by one-way ANOVA followed by Tukey post hoc test. NAC = n-acetylcysteine, DOX = doxorubicin, DOX+NAC1 = DOX+NAC treated group 1, DOX+NAC2 = DOX+NAC treated group 2. \*Significant difference at  $P < 0.05$  Vs. Control group. <sup>a</sup>Significant difference at  $P < 0.05$  Vs. DOX-treated group. •Significant difference at  $P < 0.05$  Vs. DOX+NAC2 treated group.





**Figure 4: Effect of oral administration of n-acetylcysteine on the brain level of MDA in doxorubicin-induced neurotoxicity in rats.** Each value represents the mean  $\pm$  SE. Data were analyzed by one-way ANOVA followed by Tukey post hoc test. NAC = n-acetylcysteine, DOX = doxorubicin, DOX+NAC1 = DOX+NAC treated group 1, DOX+NAC2 = DOX+NAC treated group 2. \*Significant difference at  $P < 0.05$  Vs. Control group. <sup>a</sup>Significant difference at  $P < 0.05$  Vs. DOX-treated group.

### 3.6. Changes in brain lipid peroxidation level

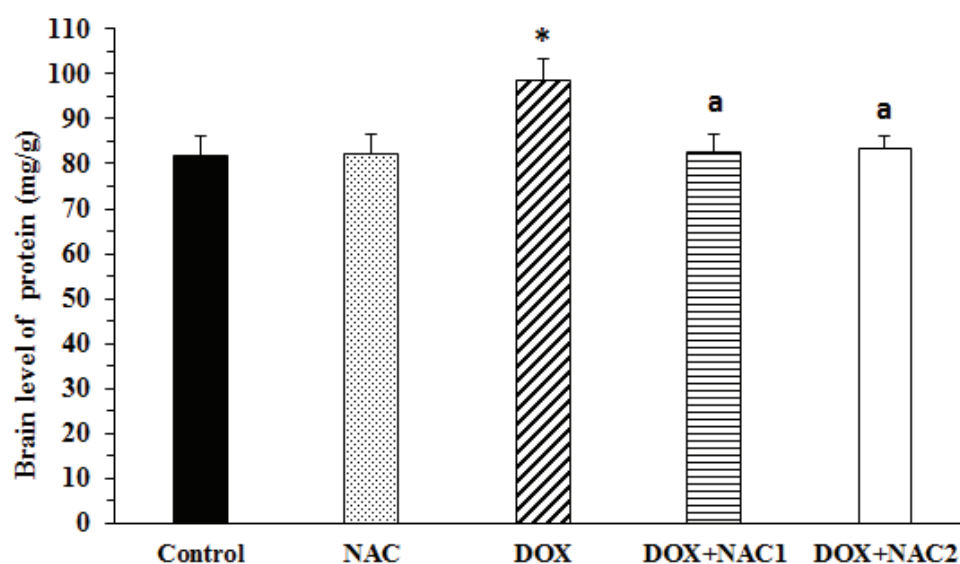
Compared to the control group, the NAC treated group showed an insignificant change ( $P > 0.05$ ) in the brain MDA level. However, the brain MDA level of the DOX-treated group was significantly increased compared to the control group and to both DOX+NAC treated groups 1 and 2 ( $P < 0.05$ ) (Figure 4). Also, the results revealed that there was an insignificant difference between DOX+NAC1 and DOX+NAC2 ( $P > 0.05$ ).

### 3.7. Changes in brain total protein level

As shown in Figure 5, the NAC treated group showed an insignificant change ( $P > 0.05$ ) in the total protein level of the brain tissue compared to the control group. However, the total protein level in the brain homogenate were significantly increased ( $P < 0.05$ ) in the DOX-treated group compared to the control group. But, the administration of NAC to DOX-treated rats resulted in a significant decrease ( $P < 0.05$ ) in the total protein level. However, an insignificant difference ( $P > 0.05$ ) between the two groups (DOX+NAC1 and DOX+NAC2) was recorded.

### 3.8. Histopathological changes

Microscopically, examination of the brain tissue of the control group revealed normal brain architecture with the cortical neurons appeared with rounded vesicular nuclei that having prominent nucleoli. Also, the cortical neurons have slight basophilic cytoplasm and peripheral processes. The neuropil contained neuroglia and nerve fibers. The blood vessels with a narrow perivascular space (Figure 6A). The NAC treated group showed normal histological features as



**Figure 5: Effect of oral administration of n-acetylcysteine on the brain level of total protein in doxorubicin-induced neurotoxicity in rats.** Each value represents the mean  $\pm$  SE. Data were analyzed by one-way ANOVA followed by Tukey post hoc test. NAC = n-acetylcysteine, DOX = doxorubicin, DOX+NAC1 = DOX+NAC treated group 1, DOX+NAC2 = DOX+NAC treated group 2. \*Significant difference at  $P < 0.05$  Vs. Control group. <sup>a</sup>Significant difference at  $P < 0.05$  Vs. DOX-treated group.

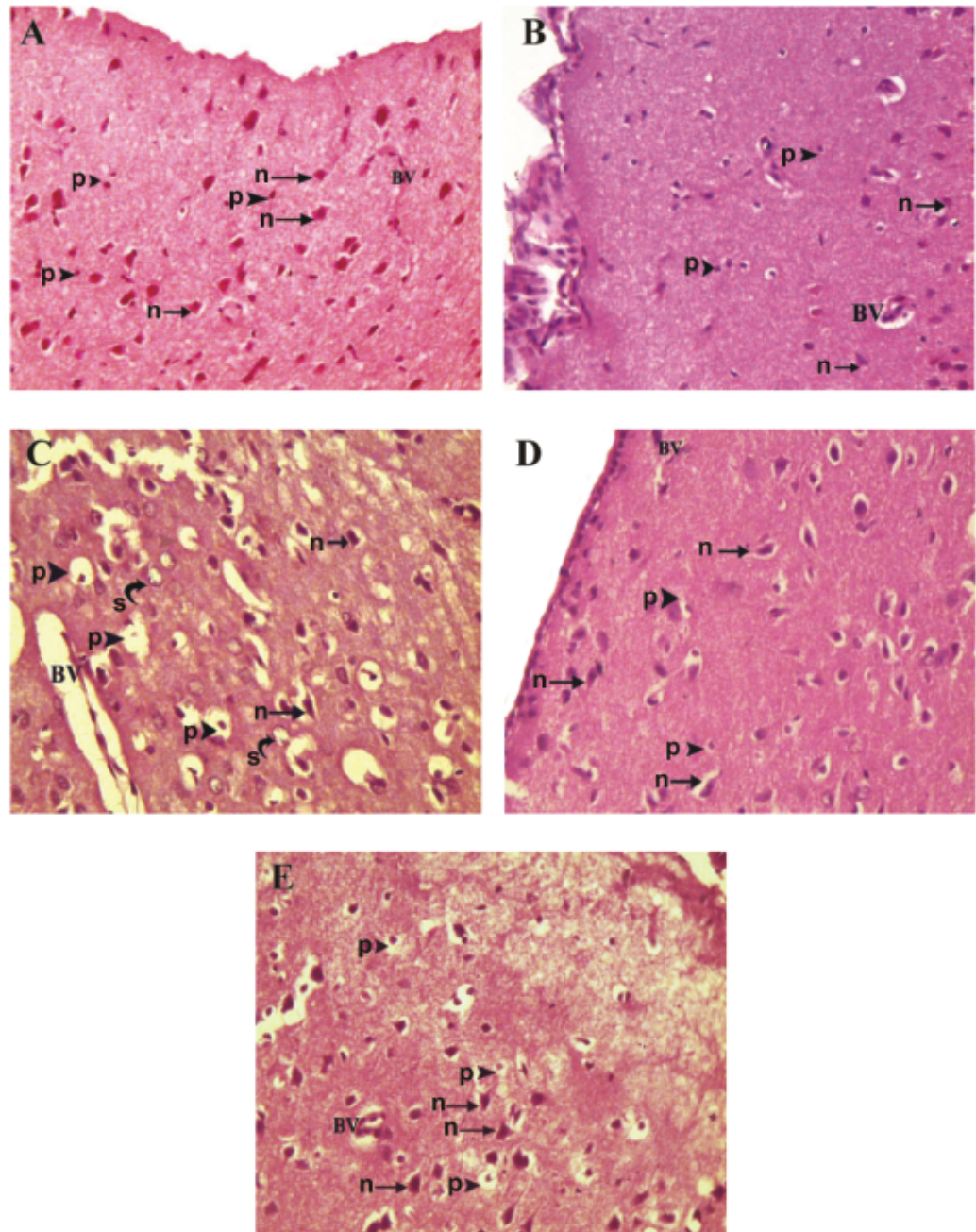
those found in the control group (Figure 6B). In the DOX-treated group, the brain tissue showed severe histopathological alteration as most of the neurons appeared shrunken with darkly stained pyknotic nuclei and surrounded by wide pericellular space (degenerated neurons). Blood vessels surrounded by wide perivascular spaces compared to the control group. Moreover, vacuolation of the neuropil was also observed in this group (Figure 6C).

Pretreatment with NAC revealed partial improvement as most of the neurons appeared similar to those of the control with decreased pericellular spaces, while others degenerated. Also, the histopathology revealed that DOX+NAC1 group showed more improvement than DOX+NAC2 (Figure 6D and 6E).

## 4. Discussion

Doxorubicin is a well-confirmed and extremely effective antineoplastic agent. However, as with most anticancer drugs, it causes many toxic effects, one of them is cognitive impairment [10]. Oxidative stress, inflammation, and apoptosis have an important role in DOX-dependent toxicity [22, 23].

This research showed that administration of 4 mg/kg of DOX (i.p.) once a week for four weeks on day 7, 14, 21 and 28 caused a brain toxicity and administration of NAC at a dose of 100 mg/kg (p.o.) was able to protect against inflammation and oxidative stress induced by DOX administration. To the best of our knowledge, this is the first study that revealed NAC potency as a neuroprotective agent by preventing inflammation and oxidative stress in DOX-induced brain damage.



**Figure 6: Photomicrographs of the brain tissue showing effects of oral administration of n-acetylcysteine in doxorubicin-induced neurotoxicity in rats.** (A) Brain tissue of the control group showing normal brain architecture; cortical neurons (n, arrow). Intercellular neuropils show different types of neuroglia and nerve fibers (p, arrow head). Blood vessels with narrow perivascular spaces (BV) (H&E x400). (B) Brain tissue of the NAC treated group showing normal brain architecture; the histological features as those found in the control group (H&E x400). (C) Brain tissue of the DOX-treated group showing severe histopathological alteration; most of the neurons appeared shrunken (n, arrow) with wide pericellular space (s, curve arrow), vacuolations in the neuropil (p, arrow head), blood vessels are surrounded by wide perivascular space (BV). (H&Ex400). (D) Brain tissue of the DOX+NAC1 group showing partial improvement as most of the neurons appeared similar to those of the control group with decreased pericellular spaces (n, arrow) (H&Ex400). (E) Brain tissue of the DOX+NAC2 group showing partial improvement as most of the neurons appeared similar to those of the control group with decreased pericellular spaces (n, arrow) but to a lesser degree than the previous group (H&Ex400).

In the present study, rats of the DOX-treated group appeared weak with evident of ascites. Necrosis was also observed at the site of DOX injection. These observations were analogous to the study of Jambhulkar et al. [24]. The administration of NAC together with DOX in both DOX+NAC1 and DOX+NAC2 groups did not prevent the occurrence of these side effects but they were less pronounced.

Moreover, mortality was observed in the DOX-treated group (30% mortality). In other DOX studies, mortality was ranged from 30-60% [24, 24, 26]. The administration of NAC with DOX in the present study decreased the toxic effect of DOX which indicated by mortality reduction to be 10% and 0% in DOX+NAC2 and DOX+NAC1 groups, respectively.

Furthermore, in the present study, regardless the presence of ascites, there was a significant decrease in the final body weight in the DOX-treated group compared to the control group which may be due to diminishing animals' food intake. Increase brain weight to body weight ratio of the DOX-treated group, in the present study, may be attributed to brain edema resulting from inflammation and oxidative stress [27]. The administration of NAC with DOX in the present study improved the effect of DOX on body weight and on brain weight to body weight ratio.

To evaluate the role of NAC in preventing the brain damage induced by DOX administration, this research conducted the analysis of brain TNF- $\alpha$ , GSH, GPx, MDA and total protein levels. Moreover, a histopathological study was performed.

Tumor necrosis factor - $\alpha$  is a cytokine that has a role in immune response as a reaction to several stresses. Also, it is the cause of cognitive damage in neurodegenerative diseases and stimulates the inflammatory response, which causes many of the clinical problems [9].

The present study found an increase in the TNF- $\alpha$  level in the brain tissue of DOX-treated group compared to the control group. This observation agreed with the results of Kuzua et al. [23] who reports a significant increase in TNF- $\alpha$  level in both heart and brain tissues after DOX administration. Moreover, Abdel-Daim et al. [28] demonstrated that DOX induced an acute inflammatory reaction, evidenced by elevation in the serum of TNF- $\alpha$  level.

Increase brain TNF- $\alpha$  level was due to the increase in the level of circulating TNF- $\alpha$  which crosses the BBB and activates glial cells to produce more TNF- $\alpha$  which leads to mitochondrial damage [29]. Moreover, increasing the TNF- $\alpha$  level played a role in chronic inflammation, which leads to neuronal death and neurodegenerative diseases. Therefore, the elevation in TNF- $\alpha$  level may be the linkage between DOX-induced oxidative stress and central nervous system damage [9].

The increased level of reactive oxygen species (ROS) can be expressed by a decrease in GSH level [30]. According to the results obtained from the current study, there was a massive decrease in the brain GSH level in the DOX-treated group compared to the control group. GSH is an intracellular non-enzymatic antioxidant and one of the most important scavengers of free radicals. Also, it is a co-factor of many detoxifying enzymes against oxidative stress as GPx and glutathione reductase [30–32].

In the present study, GSH depletion may cause a weakening in the cell defense that may lead to tissue injury. GSH is utilized as a substrate for GPx activities, therefore, its deficiency, in the present study, might be the cause of decreased GPx activities.

Glutathione peroxidase converts H<sub>2</sub>O<sub>2</sub> and organic hydroperoxides to less reactive products [33]. Hence, it is hypothesized that the decrease in the GPx activity might cause the H<sub>2</sub>O<sub>2</sub>

accumulation and a further inactivation in its activities [34]. Consequently, the brain becomes even more susceptible to oxidative processes.

In this study, the MDA level in the brain tissue of the rats was measured as a reference to the neurotoxic effect of DOX. The results revealed that administration of DOX significantly increased the MDA level and this finding was closely similar to those observed by other studies [9, 28, 29, 35]. Elevated MDA level in DOX group suggests enhanced lipid peroxidation leading to brain tissue damage and inability of antioxidant defense mechanisms to prevent the free radical attack. Furthermore, the decrease in GSH levels might diminish the overall antioxidant potential resulting in the increase of lipid peroxidation following DOX administration [36].

Increased level of brain total protein concentration may be attributed to oxidative stress and depletion of the intrinsic antioxidant machinery [24].

The histopathological analysis also confirmed that DOX produced gross structural abnormalities in brain tissue, which was in line with Ramalingayya et al. [37].

The main mechanism of DOX action is chelating DNA, inhibiting topoisomerase II and then producing free radicals to kill tumor cells [2]. As a result, it produces massive amounts of reactive oxygen species (ROS) in defense against solid tumors and this mechanism of action is involved in the toxicity of several non-targeted organs [38]. Moreover, the quinone in DOX undergoes a one-electron reduction to produce a semiquinone, which in turn react with molecular oxygen and provide other ROS [39].

In the present study, NAC alone has no significant effect on all biochemical and histopathological findings in the brain of normal rats. However, it significantly prevented all DOX-induced brain injuries possibly due to its anti-inflammatory and neuroprotective effects [40]. The administration of NAC produced a statistically significant decrease in TNF- $\alpha$  level compared to the DOX group, which agreed with the results of Saleh [41] who reported that NAC in a dose of 75 mg/kg and 600 mg/kg improved neurological functions, prevented brain inflammation and oxidative stress responses in aspartame-induced neurotoxicity. Also, Palacio et al. [13] revealed that NAC inhibits the inflammatory cytokines TNF- $\alpha$ , IL-1b and IL-6 in lipopolysaccharide-activated macrophages cell line under mild oxidative conditions. NAC prevents the generation of TNF- $\alpha$  through inhibition of the transcription factor NF-kappa B and by increasing the intracellular levels of GSH which acts as an antioxidant [11, 42].

N-acetylcysteine is known to be an antioxidant [43], and this concept is supported by the present finding that administration of NAC produced a statistically significant increase in GSH and GPx levels. The uniqueness of NAC is most probably due to its serving as a precursor of L-cysteine for GSH synthesis [11] and supplying GSH for GSH-Px-catalysed reactions [44]. Therefore, inhibition of cysteine uptake causes cellular glutathione to decrease and cellular oxidant to accumulate leading to cell death [45]. The normalization of MDA following NAC treatment is very likely due to its antiperoxidative properties [36, 43], as the presence of acetyl and sulfhydryl groups makes NAC an effective inhibitor of lipid peroxidation [36].

Generally, the present biochemical findings were strongly supported by histopathological changes in brain tissue, as NAC treatment reduced the histopathological abnormalities induced by DOX in the brain tissues. These findings agreed with Saraswathy et al. [15] who revealed that NAC in a dose of 100 and 200 mg/kg protected the brain tissue against phenytoin-induced brain damage. Moreover, Abdel-Daim et al [46] confirmed that NAC by its antioxidant power improved the histopathological abnormalities induced by fipronil in hepatic and renal tissues.

In conclusion, the results of our study showed that n-acetylcysteine by its anti-inflammatory and antioxidant properties might play an important role in the protection against doxorubicin-induced neurotoxicity in rats. Also, n-acetylcysteine not only could improve the neurotoxicity of doxorubicin but also its administration before the beginning of the chemotherapeutic agent (in DOX+NAC treated group1) provided a more benefit as it produced a significant increase in the brain GSH and GPx levels and more improvement in the histopathological abnormalities of the brain tissue.

## Funding

No funding resources.

## Competing Interests

The authors declare no competing interests.

## References

- [1] J. S. Wefel, A. K. Saleeba, A. U. Buzdar, and C. A. Meyers, "Acute and late onset cognitive dysfunction associated with chemotherapy in women with breast cancer," *Cancer*, vol. 116, no. 14, pp. 3348–3356, 2010.
- [2] J. Chen, R. Hu, and H. Chou, "Quercetin-induced cardioprotection against doxorubicin cytotoxicity," *Journal of Biomedical Science*, vol. 20, no. 1, p. 95, 2013.
- [3] US National Cancer Institute, *Adult soft tissue sarcoma treatment (PDQ): Stage IV adult tissue sarcoma*, 2014, <http://www.cancer.gov/cancertopics/pdq/> page 8.
- [4] C. E. Jansen, B. A. Cooper, M. J. Dodd, and C. A. Miaskowski, "A prospective longitudinal study of chemotherapy-induced cognitive changes in breast cancer patients," *Supportive Care in Cancer*, vol. 19, no. 10, pp. 1647–1656, 2011.
- [5] J. Tangpong, M. P. Cole, R. Sultana et al., "Adriamycin-induced, TNF- $\alpha$ -mediated central nervous system toxicity," *Neurobiology of Disease*, vol. 23, no. 1, pp. 127–139, 2006.
- [6] C. D. Aluise, R. Sultana, J. Tangpong et al., "Chemo Brain (Chemo Fog) as a potential side effect of doxorubicin administration: Role of cytokine-induced, oxidative/nitrosative stress in cognitive dysfunction," *Advances in Experimental Medicine and Biology*, vol. 678, pp. 147–156, 2010.
- [7] L. A. A. Gilliam, J. S. Moylan, L. F. Ferreira, and M. B. Reid, "TNF/TNFR1 signaling mediates doxorubicin-induced diaphragm weakness," *American Journal of Physiology-Lung Cellular and Molecular Physiology*, vol. 300, no. 1, pp. 225–231, 2011.
- [8] G. Joshi, C. D. Aluise, M. P. Cole et al., "Alterations in brain antioxidant enzymes and redox proteomic identification of oxidized brain proteins induced by the anti-cancer drug adriamycin: implications for oxidative stress-mediated chemobrain," *Neuroscience*, vol. 166, no. 3, pp. 796–807, 2010.
- [9] S. Siswanto, W. Arozal, V. Juniantito, A. Grace, and F. D. Agustini, "The effect of mangiferin against brain damage caused by oxidative stress and inflammation induced by doxorubicin," *HAYATI Journal of Biosciences*, vol. 23, no. 2, pp. 51–55, 2016.
- [10] J. Tangpong, S. Miriyala, T. Noel, C. Sinthupibulyakit, P. Jungsuwadee, and D. K. St Clair, "Doxorubicin-induced central nervous system toxicity and protection by xanthone derivative of *Garcinia mangostana*," *Neuroscience*, vol. 175, pp. 292–299, 2011.
- [11] Y. Samuni, S. Goldstein, O. M. Dean, and M. Berk, "The chemistry and biological activities of N-acetylcysteine," *Biochimica et Biophysica Acta (BBA) - General Subjects*, vol. 1830, no. 8, pp. 4117–4129, 2013.
- [12] I. Elbini Dhouib, M. Jallouli, A. Annabi, N. Gharbi, S. Elfazaa, and M. M. Lasram, "A minireview on N-acetylcysteine: An old drug with new approaches," *Life Sciences*, vol. 151, pp. 359–363, 2016.
- [13] J. R. Palacio, U. R. Markert, and P. Martínez, "Anti-inflammatory properties of N-acetylcysteine on lipopolysaccharide-activated macrophages," *Inflammation Research*, vol. 60, no. 7, pp. 695–704, 2011.
- [14] R. Bavarsad Shahripour, M. R. Harrigan, and A. V. Alexandrov, "N-acetylcysteine (NAC) in neurological disorders: mechanisms of action and therapeutic opportunities," *Brain and Behavior*, vol. 4, no. 2, pp. 108–122, 2014.

- [15] G. R. Saraswathy, E. Maheswari, T. Santhrani, and J. Anbu, "N-acetylcysteine alleviates phenytoin-induced behavioral abnormalities in rats," *International Journal of Pharmaceutical Sciences and Research*, vol. 5, pp. 3279–3292.
- [16] X.-J. Zhang, X.-Q. Cao, C.-S. Zhang, and Z. Zhao, "17 $\beta$ -estradiol protects against doxorubicin-induced cardiotoxicity in male Sprague-Dawley rats by regulating NADPH oxidase and apoptosis genes," *Molecular Medicine Reports*, vol. 15, no. 5, pp. 2695–2702, 2017.
- [17] E. Beutler, O. Duron, and B. M. Kellin, "Improved method for the determination of blood glutathione," *The Journal of Laboratory and Clinical Medicine*, vol. 61, pp. 882–888, 1963.
- [18] D. E. Paglia and W. N. Valentine, "Studies on the quantitative and qualitative characterization of erythrocyte glutathione peroxidase," *The Journal of Laboratory and Clinical Medicine*, vol. 70, no. 1, pp. 158–169, 1967.
- [19] H. Ohkawa, N. Ohishi, and K. Yagi, "Assay for lipid peroxides in animal tissues by thiobarbituric acid reaction," *Analytical Biochemistry*, vol. 95, no. 2, pp. 351–358, 1979.
- [20] M. M. Bradford, "A rapid and sensitive method for the quantitation of microgram quantities of protein utilizing the principle of protein dye binding," *Analytical Biochemistry*, vol. 72, no. 1-2, pp. 248–254, 1976.
- [21] J. D. Bancroft and M. Gamble, "Theory and practice of histological techniques," *Histopathology*, Churchill Livingstone, Edinburgh, London, 5th edition, 2002.
- [22] E. M. Mantawy, W. M. El-Bakly, A. Esmat, A. M. Badr, and E. El-Demerdash, "Chrysin alleviates acute doxorubicin cardiotoxicity in rats via suppression of oxidative stress, inflammation and apoptosis," *European Journal of Pharmacology*, vol. 728, no. 1, pp. 107–118, 2014.
- [23] M. Kuzu, F. M. Kandemir, S. Yildirim, S. Kucukler, C. Caglayan, and E. Turk, "Morin attenuates doxorubicin-induced heart and brain damage by reducing oxidative stress, inflammation and apoptosis," *Biomedicine & Pharmacotherapy*, vol. 106, pp. 443–453, 2018.
- [24] S. Jambhulkar, S. Deshiredy, and D. Babu, "Quercetin attenuating doxorubicin induced hepatic, cardiac and renal toxicity in male Albino wistar rats," *American Journal of Phytomedicine and Clinical Therapeutics*, vol. 2, no. 8, pp. 985–1004, 2014.
- [25] N. Siveski-Iliskovic, N. Kaul, and P. K. Singal, "Probuocol promotes endogenous antioxidants and provides protection against adriamycin-induced cardiomyopathy in rats," *Circulation*, vol. 89, no. 6, pp. 2829–2835, 1994.
- [26] A. H. Swamy and J. Kulkarni, "Cardioprotective effect of gallic acid against doxorubicin-induced myocardial toxicity in albino rats," *Indian Journal of Health Sciences*, vol. 8, no. 1, p. 28, 2015.
- [27] P. Himadri, S. S. Kumari, M. Chitharanjan, and S. Dhananjay, "Role of oxidative stress and inflammation in hypoxia-induced cerebral edema: A molecular approach," *High Altitude Medicine & Biology*, vol. 11, no. 3, pp. 231–244, 2010.
- [28] M. M. Abdel-Daim, O. E. Kilany, H. A. Khalifa, and A. A. M. Ahmed, "Allicin ameliorates doxorubicin-induced cardiotoxicity in rats via suppression of oxidative stress, inflammation and apoptosis," *Cancer Chemotherapy and Pharmacology*, vol. 80, no. 4, pp. 745–753, 2017.
- [29] R. H. Mohamed, R. A. Karam, and M. G. Amer, "Epicatechin attenuates doxorubicin-induced brain toxicity: critical role of TNF- $\alpha$ , iNOS and NF- $\kappa$ B," *Brain Research Bulletin*, vol. 86, no. 1-2, pp. 22–28, 2011.
- [30] J. Frijhoff, P. G. Winyard, N. Zarkovic et al., "Clinical relevance of biomarkers of oxidative stress," *Antioxidants & Redox Signaling*, vol. 23, no. 14, pp. 1144–1170, 2015.
- [31] M. Valko, C. J. Rhodes, J. Moncol, M. Izakovic, and M. Mazur, "Free radicals, metals and antioxidants in oxidative stress-induced cancer," *Chemico-Biological Interactions*, vol. 160, no. 1, pp. 1–40, 2006.
- [32] K. Jomova and M. Valko, "Advances in metal-induced oxidative stress and human disease," *Toxicology*, vol. 283, no. 2-3, pp. 65–87, 2011.
- [33] Z. Yildirim and N. Kilic, "Effects of taurine and age on cerebellum antioxidant status and oxidative stress," *International Journal of Gerontology*, vol. 5, no. 3, pp. 166–170, 2011.
- [34] I. A. Finamor, G. M. Ourique, T. S. Pês et al., "The Protective Effect of N-Acetylcysteine on Oxidative Stress in the Brain Caused by the Long-Term Intake of Aspartame by Rats," *Neurochemical Research*, vol. 39, no. 9, pp. 1681–1690, 2014.
- [35] A. M. Kosoko, O. J. Olurinde, and O. A. Akinloye, "Doxorubicin induced neuro- and cardiotoxicities in experimental rats: Protection against oxidative damage by Theobroma cacao Stem bark," *Biochemistry and Biophysics Reports*, vol. 10, pp. 303–317, 2017.
- [36] I. E. B. Dhouib, A. Annabi, A. Jrad, N. Gharbi, M. M. Lasram, and S. El-Fazaa, "Protective effect of n-acetylcysteine against toxicity on the rat blood after chronic exposure to carbosulfan," *Recent Advances in Biology and Medicine*, vol. 1, pp. 18–25, 2015.
- [37] G. Ramalingayya, P. Nayak, R. Shenoy et al., "Naringin ameliorates doxorubicin-induced neurotoxicity In vitro and cognitive dysfunction In vivo," *Pharmacognosy Magazine*, vol. 14, no. 55, p. 197, 2018.
- [38] G. W. Konat, M. Kraszpulski, I. James, H.-T. Zhang, and J. Abraham, "Cognitive dysfunction induced by chronic administration of common cancer chemotherapeutics in rats," *Metabolic Brain Disease*, vol. 23, no. 3, pp. 325–333, 2008.

- [39] F. Bulucu, R. Ocal, N. Karadurmus et al., "Effects of N-acetylcysteine, deferoxamine and selenium on doxorubicin-induced hepatotoxicity," *Biological Trace Element Research*, vol. 132, no. 1-3, pp. 184–196, 2009.
- [40] A. Prakash, J. K. Kalra, and A. Kumar, "Neuroprotective effect of N-acetyl cysteine against streptozotocin-induced memory dysfunction and oxidative damage in rats," *Journal of Basic and Clinical Physiology and Pharmacology*, vol. 26, no. 1, pp. 13–23, 2015.
- [41] A. A. Saleh, "Anti-neuroinflammatory and antioxidant effects of N-acetyl cysteine in long-term consumption of artificial sweetener aspartame in the rat cerebral cortex," *The Journal of Basic & Applied Zoology*, vol. 72, pp. 73–80, 2015.
- [42] M. Beppu, S. Sawai, S. Misawa et al., "Serum cytokine and chemokine profiles in patients with chronic inflammatory demyelinating polyneuropathy," *Journal of Neuroimmunology*, vol. 279, no. C, pp. 7–10, 2015.
- [43] M. Zafarullah, W. Q. Li, J. Sylvester, and M. Ahmad, "Molecular mechanisms of N-acetylcysteine actions," *Cellular and Molecular Life Sciences*, vol. 60, no. 1, pp. 6–20, 2003.
- [44] F. Saricaoglu, D. Dal, A. E. Salman et al., "Effect of low-dose N-acetyl-cysteine infusion on tourniquet-induced ischaemia-reperfusion injury in arthroscopic knee surgery," *Acta Anaesthesiologica Scandinavica*, vol. 49, no. 6, pp. 847–851, 2005.
- [45] A. Prakash and A. Kumar, "Effect of N-Acetyl cysteine against aluminium-induced cognitive dysfunction and oxidative damage in rats," *Basic & Clinical Pharmacology & Toxicology*, vol. 105, no. 2, pp. 98–104, 2009.
- [46] M. M. Abdel-Daim, A. A. Dessouki, H. G. Abdel-Rahman, R. Eltaysh, and S. Alkahtani, "Hepatorenal protective effects of taurine and N-acetylcysteine against fipronil-induced injuries: The antioxidant status and apoptotic markers expression in rats," *Science of the Total Environment*, vol. 650, pp. 2063–2073, 2019.